

Long-Term Evaluation of the Long-Pulsed Alexandrite Laser for the Removal of Bikini Hair at Shortened Treatment Intervals

JENIFER R. LLOYD, DO* AND MIRKO MIRKOV, PHD†

*Department of Clinical Internal Medicine, Northeastern Ohio University College of Medicine, Rootstown, Ohio, and

†Cynosure, Inc., Chelmsford, Massachusetts

BACKGROUND. Laser-assisted hair removal is becoming the treatment of choice for removing unwanted hair.

OBJECTIVE. The purpose of this work was to determine the long-term efficacy of the long-pulsed infrared (LPIR) laser at shortened treatment intervals for the treatment of bikini hair.

METHODS. Eleven patients received five treatments at 3-week intervals to the right groin using the LPIR laser. Laser parameters were held constant for all treatments: 10 mm spot size, 20 J,

and 20-msec pulse duration. Results were evaluated 1 year after the last laser treatment. Hair counts were performed.

RESULTS. The average patient had a 78% clearance of hair noted at 1 year with no evidence of scarring or pigmentary changes.

CONCLUSIONS. A simulated model of cutaneous hair follicles provides evidence that shorter treatment intervals (3 weeks) may be preferable for more complete destruction of the hair follicle bulb and bulge.

UNWANTED BIKINI HAIR is a cosmetic concern to many women. Numerous treatment options for removing this unwanted hair have been used, including shaving, tweezing, waxing, and chemical depilatories.¹⁻³ Unfortunately these methods are only temporary, with hair returning within hours to weeks. Electrolysis^{4,5} has been promoted as a permanent method of hair removal; however, it is not commonly performed in this area because of it is a tedious and time-consuming procedure.

Laser-assisted hair removal using a topical carbon-particle suspension followed by treatment with the Q-switched Nd:YAG laser was the first FDA approved laser treatment used for the removal of unwanted hair.⁶ This treatment method has been reported to delay hair regrowth up to 3 months,^{7,8} but has not been reported to give permanent hair reduction.

The theory of selective photothermolysis developed by Anderson and Parrish^{9,10} allows for targeting of a given chromophore by choosing a laser system that emits an appropriate wavelength and pulse duration of light. By applying this theory the target can be selectively destroyed without damage to the surrounding tissue. The first application of this theory for the re-

moval of hair was reported in 1996 by Grossman et al.¹¹ using the normal mode ruby laser. Dierickx et al.¹² published 2-year follow-up observations, demonstrating long-term permanent hair reduction with the normal mode ruby laser.

Recently the market has exploded, with numerous lasers and light sources now available for the treatment of unwanted hair. This technology is quickly becoming the treatment of choice, although very few studies are available to demonstrate its long-term effectiveness.

This study was designed to evaluate the long-term efficacy of the PhotoGenica LPIR laser for the removal of unwanted bikini hair. This alexandrite laser system, with an output of 755 nm, is well absorbed by the follicular melanin. In addition, the long pulse duration of this laser system allows for selective treatment of the hair follicle with less damage to the surrounding tissues, embracing the principles of selective photothermolysis.⁹

Materials and Methods

Eleven consenting patients (10 women, 1 man) volunteered to receive laser treatment to their right groin for the removal of unwanted bikini hair. Institutional review board (IRB) approval was obtained prior to this study. Patients ranged in age from 16 to 46 years old with skin types I-III. All patients had black pubic hair. Baseline photographs were obtained using identical lighting and patient positioning to document the pretreatment bikini hair. Prior to laser exposure, the treatment area was clipped using electric hair clippers and coated with KY surgical lubricant. No anesthesia was used and all patients wore protective eyewear. The right

J.R. Lloyd, DO has indicated no significant financial interest with commercial supporters. M. Mirkov, PhD is an employee of Cynosure, Inc., Chelmsford, MA.

Address correspondence and reprint requests to: Jenifer R. Lloyd, DO, Lloyd Dermatology and Laser Center, 8060 Market St., Youngstown, OH 44512, or e-mail: jrl2@neoucom.edu.

groin was treated by the physician from the inguinal fold onto the thigh with the PhotoGenica LPIR laser (Cynosure, Inc., Chelmsford, MA) using identical laser parameters: 755 nm wavelength, 20-msec pulse duration, 20 J/cm² fluence, 10 mm handpiece with no more than a 10% pulse overlap. The patients returned at 3-week intervals for re-treatment to the right groin for a total of five treatments. Twelve months after the last treatment, patients returned for photographs. Patients were instructed not to pluck, shave, wax, or epilator for at least 6 weeks before returning for follow-up photographs. The pre- and posttreatment photographs were used to perform computer-enhanced hair counts.

Results

Assessment of the patients' treatment results were photographically evaluated and hair counts were performed for all patients both pretreatment and again 1 year following the last laser treatment. All patients in this study had a marked reduction in hair at the treatment site (Figure 1). Table 1 lists the patient's hair counts

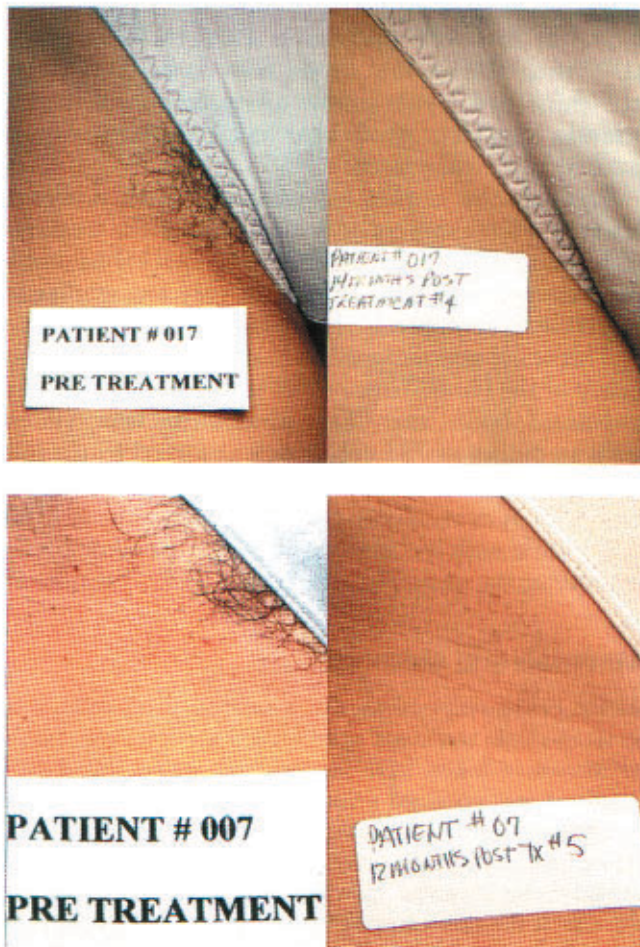


Figure 1. Photographs demonstrating excellent results 1 year after the last laser treatment.

Table 1. Patient Hair Counts and the Percentage Clearance 1 Year After Their Last Treatment

Patient	Hair count before	Hair count after	Clearance (%)
2	106	26	75
4	40	4	90
5	54	3	94
6	42	6	86
7	61	1	98
8	61	17	72
10	74	18	76
11	67	3	96
12	170	94	45
14	97	53	45
18	197	28	86
Mean			78
Median			86

as well as the percentage of clearance found 1 year after their last laser treatment. The mean clearance of hairs was 78% and the median clearance was 86%. The data is statistically significant with $P < .02$.

All patients tolerated the procedure well. Erythema and mild perifollicular edema were noted immediately after the procedure which resolved within hours. No patients had to alter their skin care routines following laser treatment. Two patients (14%) were noted to develop transient hypopigmentation following the first laser treatment. There was no evidence of pigmentary alterations noted at the 1-year follow-up. No scarring or purpura was documented.

It is of interest that when patients returned for their subsequent laser treatments, no hairs were evident at the treated site. Additional treatments were rendered according to the protocol despite the lack of visible hair growth.

Discussion

In this quickly growing laser market, numerous laser and light systems are available for removal of unwanted hair.¹³ However, there are few studies to determine long-term efficacy. The results of this study suggest that the LPIR laser is a safe and effective modality for use in the long-term reduction of unwanted bikini hair.

This long-pulsed alexandrite laser system exerts its effect on the hair follicle by applying the principles of selective photothermolysis.⁹ With a wavelength of 755 nm, the laser energy is able to penetrate deep into the dermis and selectively target follicular melanin.¹⁰ In addition, a 20-msec pulse duration was chosen to minimize interference from epidermal melanin and maximize destruction of the hair follicle. This pulse duration lies above the thermal relaxation for the epidermis,

which is estimated to be 3–10 msec, and below the thermal relaxation time of the hair follicles, which is estimated to be 40–100 msec, thereby optimizing selective destruction of the hair follicle.

Numerous articles have suggested that multiple laser treatments yield more effective clinical results.^{11,14,15} Because of the oncoming bikini season, a 3-week treatment interval was chosen to allow for multiple laser treatments. This 3-week treatment interval is shorter than the usually adopted treatment interval of 6–12 weeks.¹⁶ A relatively long waiting period between treatments has been widely adopted under the assumption that the best time to treat the follicle is in the late telogen/early anagen phase. The long interval of 6–12 weeks also allows the hair to regrow to the point where it is visible on the skin surface, ensuring the presence of a target for the laser. The presence of at least part of the hair is necessary to provide a target for the laser radiation. For example, it has been observed that epilation of the hair prior to laser treatment produces poor long-term results.¹¹ However, it is not clear yet which part of the hair follicle has to be destroyed to achieve long-term hair removal.

There have been a number of publications investigating the relationship between hair follicle damage and hair regrowth. The importance of both the bulge¹⁷ and bulb¹⁸ regions has been emphasized. Some authors have established the bulge activation hypothesis based on their findings that the follicular stem cells reside in the bulge region of the hair follicle.¹⁷ It has been suggested by Dierickx et al.¹⁹ that the probability for laser hair destruction is independent of the hair growth cycle. These authors propose that since the location of the bulge is independent of the growth cycle, the stem cells in the bulge are the main target for permanent hair removal, advocating that the bulge has to be destroyed to prevent hair growth. Contrary to these findings, Liew et al.¹⁸ observed that thermal damage to the bulge region, without thermal damage to the bulb, provides only temporary hair reduction. These authors suggest that the destruction of the bulge is not sufficient and that the bulb has to be destroyed as well to achieve permanent hair reduction. From these articles we can conclude that both regions play an important role and that it would be beneficial for permanent hair removal to increase the efficiency of the energy delivery to both the hair follicle bulge and bulb.

One possible advantage of this shortened treatment interval is that in 3 weeks the hair has begun to regrow in the bulb, but it has not yet grown to the surface of the skin. This would imply that there is a sufficient amount of melanin in the follicle bulb to serve as a target for the laser; however, with hairs not yet to the skin's surface, there would be less absorption of laser energy by the hair shafts embedded in the dermis.

Thus with smaller hair shaft absorption in the dermis, a larger fraction of the laser energy is delivered to the follicle bulb and the bulge. This may represent the main benefit of the 3-week treatment plan.

The effect of hair in the dermis was evaluated by modeling the fluence distribution in the skin in the presence and absence of hair using a Monte Carlo simulation package.^{20,21} The software simulates the irradiation of a scattering and absorbing stratified medium by following a large number of photons through individual absorption and scattering events. The results of the calculation include the spatial distribution of the fluence and the amount of energy deposited in the tissue.

The skin structure with embedded hair follicles was represented as a stratified medium using a number of simplifying assumptions. The average follicle count on the untreated legs and thighs is about 60 follicles/cm².²² It is assumed that the average hair follicle bulb is a sphere with a diameter of 200 μ m and that the average follicle bulb depth is 3 mm.^{11,22} In addition, it is assumed that the hair follicle bulb contains 100% melanin. The presence of hair follicle bulbs with a density of 60 bulbs/cm² was simulated by a 200 μ m skin layer with 1.26% distributed melanin content at a depth of 3 mm. With these assumptions, the equivalent of 0.47% distributed melanin content in the dermis would decrease the penetration ability of the laser radiation. The presence of hairs in the dermis was modeled by a dermal layer containing 0.47% of melanin positioned above the follicle bulb layer. The thickness of the hair shaft layer was varied to simulate the process of hair growth. The model laser parameters were identical with the laser used in the study: input beam diameter 10 mm, input fluence 20 J/cm², and wavelength 755 nm.

The definition of fluence is the total amount of photon energy density available at a given coordinate. Knowledge of the fluence distribution and the absorption coefficient of the structures of interest allow for calculation of the energy density deposited in these structures. The center beam fluence distribution versus depth is plotted in Figure 2. The presence of 0.47% distributed melanin content in the dermis, representing the presence of hairs extending to the surface of the skin, reduces the fluence at the bulb depth by approximately a factor of two. The presence of hair also reduces the fluence by 40% at the average bulge depth of 1 mm.

The amount of laser energy deposited per unit volume of tissue can be calculated by multiplying the fluence at a given depth by the corresponding absorption coefficient in the tissue. The deposited energy is the heat source that damages the hair follicle structures. The total amount of energy deposited in a tissue layer

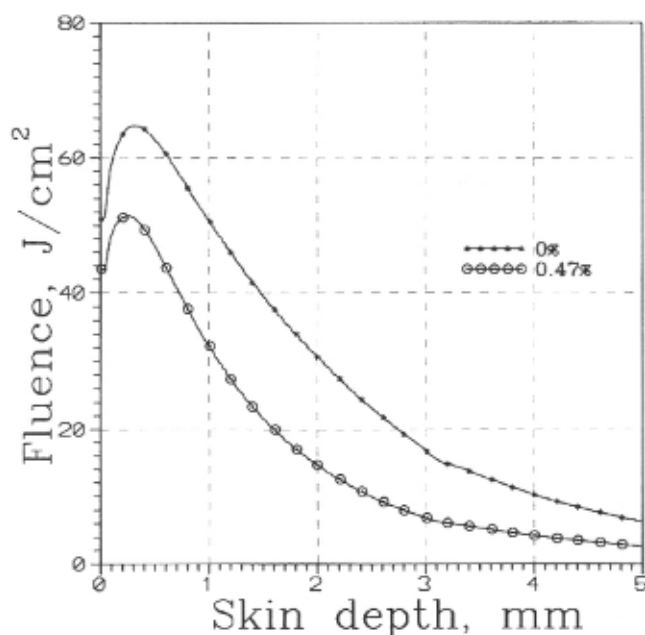


Figure 2. On-axis fluence versus depth in the presence and absence of distributed hair content. The input beam diameter is 10 mm, input fluence 20 J/cm², wavelength 755 nm.

can be calculated by integrating this energy per unit volume over the volume of that layer. Specifically in our model, the follicle bulbs are assumed to occupy only 1.26% of the volume in the follicle bulb layer, but due to their high absorption they receive nearly all the energy deposited in that layer. In order to calculate the energy effectively deposited in the bulbs, the value for deposited energy in the bulb layer has to be multiplied by 1/0.0126 or approximately by 80.

The effective energy deposited in the follicle bulbs was calculated in a series of models with various hair lengths. The results are summarized in Figure 3. In this plot, fractional hair length of 0 corresponds to a short hair stem in the bulb and no hair shaft present in the dermis. The progressively larger fractional lengths represent hair shafts extending in the dermis. The fractional hair length of 1 corresponds to completely grown hair shafts that reach the surface of the skin. The solid line in Figure 3 shows that the growing hair gradually decreased the efficiency of the energy delivery to the follicle bulb. If the hair does not extend to the surface of the skin, the efficiency of the energy delivery to the bulb can be improved by as much as a factor of 2 or more compared to the case of fully grown hair.

A similar effect applies in the bulge region, where the larger fluence in the absence of hair in the skin results in an increase of the delivered energy. The dashed line in Figure 3 represents the total energy deposited in the dermis above the level of the follicle

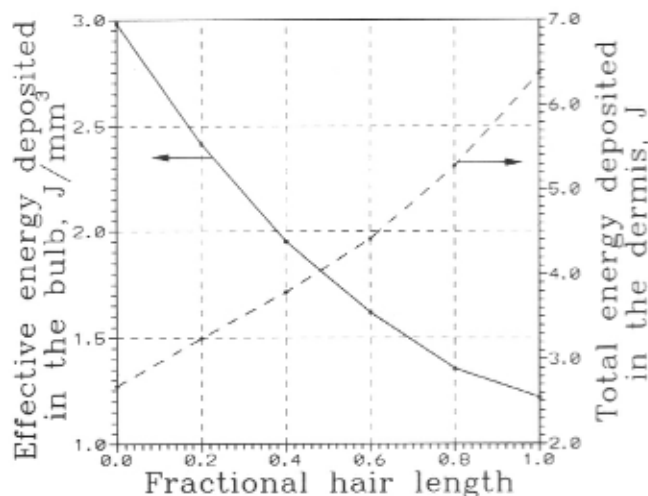


Figure 3. Solid line: on-axis effective deposited energy density in the follicle bulb versus length of hair embedded in the skin. Dashed line: total energy deposited in the dermis above the level of the follicle bulbs versus length of hair embedded in the skin. The fractional hair length 0 corresponds to the absence of hair in the dermis, 1 corresponds to the hair that has grown to the surface of the skin. The input beam diameter is 10 mm, input fluence 20 J/cm², and wavelength 755 nm.

bulbs. The dermal absorption is due to the presence of partially grown hair shafts and the dermal blood content. The dashed line in Figure 3 shows that the growing hair in the dermis absorbs a substantial amount of energy. In the case of fully grown hair, about 6.3 J of energy is deposited in the dermis and contributes only to unnecessary heating of the dermis. This is about 40% of the total pulse energy of 15.7 J incident on the skin. If the hair does not extend to the surface of the skin, the amount of energy deposited in the dermis can be reduced by a factor of 2 or more.

The conclusion from the present simulations is that the presence of developed hair shafts in the skin substantially decreased the amount of energy delivered to both the hair follicle bulb and the bulge. Therefore it would be beneficial to perform the hair removal treatments on a schedule that minimizes the presence of the highly absorbing hair shafts in the skin. The most effective treatment interval allows for the formation of a very short hair stem in the follicle bulb to serve as target for the laser light. This interval would also allow for the formation of melanotic melanocytes in the bulge area, which also serve as a target for the laser.²³ This treatment interval would also be sufficiently short to minimize hair growth in the dermis and improve the conditions for effective delivery of energy to the hair follicle bulb and the bulge. Biopsy results published by McCoy et al.¹⁶ show that 4 weeks after the initial treatment the hair follicle bulb has developed a short hair shaft and can be targeted again with the la-

ser. We have been unable to find data for the time interval needed for formation of melanotic melanocytes in the bulge region. Unfortunately pathology was not done in this study to confirm our hypothesis; however, the observed excellent hair removal results suggest that both the bulge and the bulb regions were effectively targeted.

The excellent results achieved with this long-pulsed alexandrite laser system were maintained at 1 year following the last laser treatment. The proposed definition for permanent hair reduction requires that the hair reduction be stable for a period of time longer than the complete growth cycle of follicles at a given body site.¹² The exact duration of the bikini hair cycle is unclear but is estimated to be 3–7 months.^{19,20} This study, demonstrating hair reduction stable for a year, implies that the LPIR laser is an effective tool in long-term hair reduction.

References

- Richards RN, Uy M, Meharg G. Temporary hair removal in patients with hirsutism: a clinical study. *Cutis* 1990;45:199–202.
- Wagner RF. Physical methods for the management of hirsutism. *Cutis* 1990;45:319–26.
- Marchell NL, Alster TS. Evaluation of hair removal methods. *Aesthetic Dermatol Cosmet Surg* 1999;1:3–12.
- Richards RN, McKenzie MA, Meharg GE. Electroepilation (electrolysis) in hirsutism: 35,000 hours experience on the face and neck. *J Am Acad Dermatol* 1986;15:693–7.
- Richards RN, Meharg GE. Electrolysis: observation from 13 years and 140,000 hours of experience. *J Am Acad Dermatol* 1995;33:662–8.
- Goldberg D. Topical solution-assisted laser hair removal. *Lasers Surg Med* 1995;(suppl 7):47.
- Goldberg D. Topical suspension-assisted laser hair removal: treatment of axillary and inguinal regions. *Lasers Surg Med* 1996;(suppl 8):34.
- Nanni CA, Alster TS. Optimizing treatment parameters for hair removal using a topical carbon-based solution and 1064 nm Q-switched neodymium:YAG laser energy. *Arch Dermatol* 1997;133:1546–9.
- Anderson RR, Parrish JA. Selective photothermolysis: precise microsurgery by selective absorption of pulsed radiation. *Science* 1983;220:524–7.
- Anderson RR, Parrish JA. The optics of human skin. *J Invest Dermatol* 1981;77:13–9.
- Grossman MC, Dierickx CC, Farinelli WA, Flotte T, Anderson RR. Damage to hair follicles by normal-mode ruby laser pulses. *J Am Acad Dermatol* 1996;35:889–94.
- Dierickx CC, Grossman MC, Farinelli WA, Anderson RR. Permanent hair removal by normal-mode ruby laser. *Arch Dermatol* 1998;134:837–42.
- Nanni CA, Alster TS. A practical review of laser-assisted hair removal using the Q-switched Nd:YAG, long-pulsed ruby and long-pulsed alexandrite lasers. *Dermatol Surg* 1998;24:1399–405.
- William R, Havoonjian H, Isagholian K, Menaker G, Moy R. A clinical study of hair removal using the long-pulsed ruby laser. *Dermatol Surg* 1998;24:837–42.
- Lask G, Elman M, Slatkine M, Waldman A, Rozenberg A. Laser-assisted hair removal by selective photothermolysis. *Dermatol Surg* 1997;23:737–9.
- McCoy S, Evans A, James C. Histological study of hair follicles treated with 3 msec pulsed ruby laser. *Lasers Surg Med* 1999;24:142–50.
- Costarellis G, Sun TT, Lavker RM. Label-retaining cells reside in the bulge area of pilosebaceous unit: implications for follicular stem cells, hair cycle and skin carcinogenesis. *Cell* 1990;61:1329–37.
- Liew SH, Grobbelaar AO, Gault DT, Sanders R, Green CJ, Linage C. The effect of ruby laser on ex vivo hair follicles: clinical implications. *Ann Plast Surg* 1999;42:249–54.
- Dierickx CC, Campos VB, Lin D, Farinelli W, Anderson RR. Influence of hair growth cycle on efficacy of laser hair removal [abstract]. *Proceedings of the 19th Annual Meeting of the ASLMS*, 1999.
- Wang LH, Jacques SL, Zheng LQ. MCML—Monte Carlo modeling of photon transport in multi-layered tissues. *Comput Methods Programs Biomed* 1995;47:131–46.
- Wang LH, Jacques SL, Zheng LQ. CONV—convolution for responses to a finite diameter photon beam incident on multi-layered tissues. *Comput Methods Programs Biomed* 1997;54:141–50.
- Richards RN, Meharg GE. *Cosmetic and medical electrolysis and temporary hair removal*. Toronto: Medric Ltd., 1997.
- Narisawa Y, Kohda H, Tanaka T. Three dimensional demonstration of melanocyte distribution of human hair follicles: special reference to the bulge area. *Acta Derm Venereol* 1997;77:97–101.